
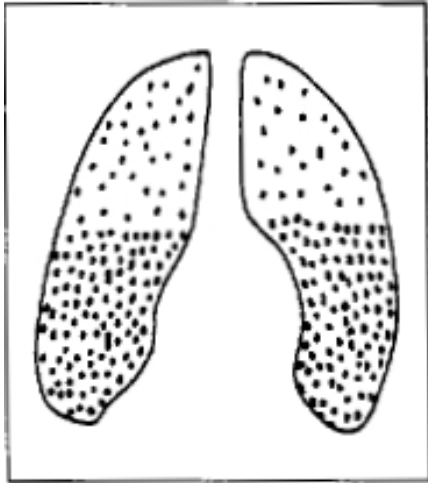


Lung Diseases

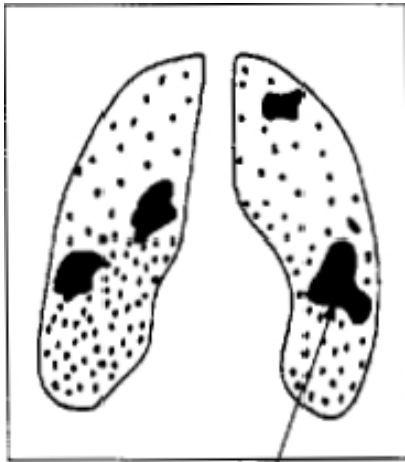


Simple



Coal Workers' Pnemuconiosis

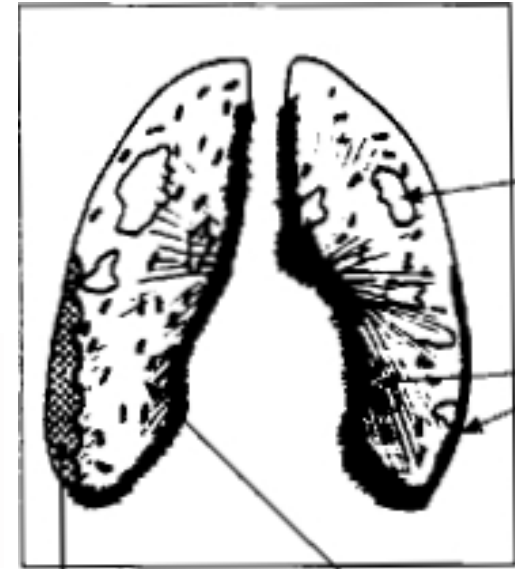
Complicated



Progressive massive fibrosis



Asbestos



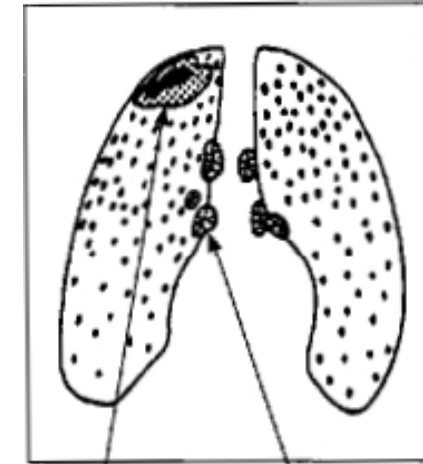
Pleural plaques

Pleural thickening

Mesothelioma

Irregular fibrosis

Silicosis



Tuberculosis

Calcified lymph nodes